



**PATIENT**

Olive Mourbe

**PRESENTING CLINICAL SIGNS**

History: Continuous heart murmur noted on routine exam. Asymptomatic. Suspect PDA.

**SPECIES**

Canine

**ECHOCARDIOGRAM FINDINGS**

2D, m-mode, color flow and doppler imaging is available. Continuous flow detected with color Doppler in the distal pulmonary artery. High velocity shunt primarily L-R (max velocity not able to be measured). Moderate volume overload of the left heart with adequate systolic function. Increased LV sphericity. Mild to moderate LA dilation. No MR. No obvious TR. Mildly elevated pulmonic outflow velocities; no pulmonic insufficiency. Mild MPA and branch dilation. The PV appears normal. Mildly elevated aortic outflow velocities with trace AI. No pericardial or pleural effusion noted. No obvious cardiac masses.

**BREED**

German Shephard

**SEX**

Female

**CARDIAC CHART**

**AGE**

4 months

**WEIGHT**

36.5lbs

CANINE CARDIAC PARAMETERS	MR VMAX (m/s)	TR VMAX (m/s)	LA/AO (Boon method)	LA/AO (Heart Base; Swe)	FS (%)	EF (%)	EPSS (cm)
NORMAL PARAMETER	4.5-5.5	<2.7	1.3	<1.6	28-40	40-100	<0.6
PATIENT	NA	NA	NM	1.6	46	77	0.3
CANINE CARDIAC PARAMETERS	HR (BPM)	AV VMAX (m/s)	PV MAX (m/s)	BODY WEIGHT (kg)	LA 2D short axis Base view (cm)	LVIDd Avg; 2D and m-mode short axis (cm)	LVIDs Avg; 2D and m-mode short axis (cm)
NORMAL PARAMETER	50-100	0.7-1.7	0.7-1.6	BELOW	BELOW	BELOW	BELOW
PATIENT	NM	2.4	1.9	16.6	3.5	5.3	2.9
*Normal chamber parameters expressed as a mean value (SD)				3	1.27 (5.3)	2.46 (2.46)	1.36 (5.5)
<b>BODY WEIGHT DEPENDENT PARAMETERS</b>				5	1.40 (4.5)	2.74 (5.2)	1.60 (4.7)
<i>*Note: All measurements based upon multi-modal images and methods. An average value is reported.</i>				10	1.50 (3.8)	3.27 (3.5)	2.06 (3.1)
				15	1.83 (2.0)	3.71 (2.4)	2.43 (2.1)
				20	2.02 (1.9)	4.14 (2.2)	2.80 (2.0)
				25	2.18 (2.4)	4.48 (2.9)	3.10 (2.5)
				30	2.33 (3.3)	4.83 (3.9)	3.39 (3.4)
				35	2.48 (4.3)	5.17 (5.0)	3.69 (4.5)
				40	2.62 (5.2)	5.48 (6.1)	3.96 (5.4)
				50	2.88 (7.1)	6.07 (8.3)	4.46 (7.4)

**INTERPRETED BY**

Maggie Machen Lamy, DVM, DACVIM (Cardiology)

**IMAGING PERFORMED BY**

Jacque Pankatz, DVM

**HOSPITAL NAME**

Mountain Vista Veterinary Hospital

**REFERRING VET**

Dr. Pankatz

**INVOICE**

22275

**DATE**

12/4/21

**INTERPRETATION OF THE FINDINGS & FURTHER RECOMMENDATIONS**

The cause of the murmur is suspected to be a patent ductus arteriosus (PDA). This is suspect as the shunt is not visualized, and other possibilities are not entirely ruled out. This is a congenital condition where a blood vessel present in the fetus remains open after birth. When patent, this allows blood to recirculate through the lungs inappropriately and volume overloads the left heart chambers as is seen here. There is also trivial MR and AI, however these are clinically insignificant at this time. It is important to note that other small congenital defects can be easily missed in these cases, and advanced imaging with a Cardiologist is recommended.

Given moderate LA/LV dilation, this patient is at risk for progression to CHF, arrhythmias, PDA reversal due to development of pulmonary hypertension, exertional syncope, and/or sudden



## PATIENT

Olive Mourbe

death at home in the future. Monitor sleeping respiratory rates at home to screen for progression to CHF.

## SPECIES

Canine

Gold standard therapy is surgical closure of the vessel. This can be done interventionally or through a thoracotomy, and consultation with a local Cardiologist is recommended if sought (**highly recommended**). Success rates for the procedure are generally high, particularly given the asymptomatic status and a good chance for a normal life if closed appropriately. Regardless of whether or not surgery is elected, cardiac support with Pimobendan is recommended for long term benefit. If surgery is not an option, prognosis is guarded to poor long term and close monitoring is advised.

## BREED

German Shephard

## SEX

Female

Omega fatty acid supplementation and mild salt restriction may be of some long-term benefit. Monitoring of sleeping breathing rates is recommended as the best way to screen for progression to CHF at home. Mild activity restriction is advised. Monitor at home for breathing changes, worsening cough, fainting episodes, exertional dyspnea.

## AGE

4 months

Plan: Institute Pimobendan 0.3mg/kg PO q12h. Recommend referral to a local Cardiologist for advanced evaluation and surgical consultation. If not an option, reassess structure and function every 6 months lifelong to assess need for additional medications, sooner if clinical signs arise (progressive cough, labored breathing, syncope).

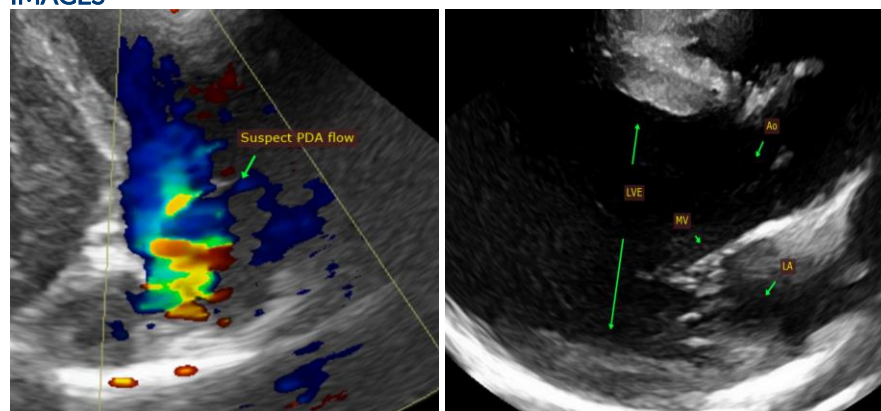
## WEIGHT

36.5lbs

## IMAGES

## INTERPRETED BY

Maggie Machen Lamy,  
DVM, DACVIM  
(Cardiology)



## IMAGING PERFORMED BY

Jacque Pankatz,  
DVM

## HOSPITAL NAME

Mountain Vista  
Veterinary Hospital

The information and recommendations provided are based on the images presented by the referring veterinarian. No evaluation can be communicated regarding pathology that was not visible in the image/video clips provided.

## REFERRING VET

Dr. Pankatz

Thank you for this referral. This report was generated using transcription software, and minor dictation errors may be present. If the clinical or image interpretation does not parallel your findings or if I can be of any further assistance, please contact me.

## INVOICE

22275

**Maggie Machen Lamy, DVM**  
Diplomate of the American College of Veterinary Internal Medicine (Cardiology)  
info@sonopath.com

## DATE

12/4/21